

Dehydrated Human Amnion/Chorion Membrane (dHACM) Allografts as a Therapy for Orthopedic Tissue Repair

Jennifer Lei, PhD,* Lauren B. Priddy, PhD,† Jeremy J. Lim, PhD,*
and Thomas J. Koob, PhD*

Summary: The amniotic membrane is a placental tissue that supports the development of the fetus during pregnancy. It is composed of extracellular matrix components such as collagen, fibronectin, and laminin, and contains many different growth factors and cytokines. Amniotic membrane can be PURION® Processed to produce dehydrated human amnion/chorion membrane (dHACM, Epifix, Amniofix; MiMedx Group Inc.) allografts. This tissue has been shown in randomized clinical trials to be effective for healing chronic foot and leg ulcers, and has demonstrated the ability to promote the migration of stem cells in vitro and to recruit stem cells to a wound site in vivo. Owing to its regenerative properties, amniotic membrane and dHACM allografts have more recently been implicated as an alternative or supplemental therapy in the treatment of orthopedic tissue injuries such as plantar fasciitis, tendinopathy, and vertebral fusion procedures. In this review, the basic structure, function, and components of dHACM are discussed, and its current in vitro, in vivo, and clinical usages in orthopedic tissue repair applications are summarized.

Key Words: amniotic membrane—dehydrated human amnion/chorion membrane—tissue repair and regeneration—growth factors.

(*Tech Orthop* 2017;00: 000–000)

AMNIOTIC MEMBRANE

Structure and Function of Amniotic Membranes

The placenta plays a critical role in transporting nutrients and protecting the fetus during pregnancy. The developing fetus and amniotic fluid are enclosed in the amniotic sac of the placenta, circumscribed by the amniotic membrane, which functions to help modulate the contents of the intra-amniotic compartment and mediates the interaction between the fetal and maternal tissues. The amniotic membrane is composed of 2 distinct layers that surround the embryo: the amnion that lines the inner surface of the amniotic sac interfacing with the fetus, and the chorion that is the outer layer in contact with maternal tissue.^{1,2} The amnion layer is composed of an

epithelial layer, a basement membrane, a compact layer, and a fibroblast layer. Collagens type I and type III are located in the fibroblast layer and provide most of the tissue's mechanical strength. Collagen type V and type VI create filamentous cross-links between the fibrous network and the basement membrane that contains collagen type IV.^{3,4} Other extracellular matrix (ECM) components, such as fibronectin and laminin, are found throughout the amnion tissue.⁵ An intermediate spongy layer separates the amnion and chorion with a jelly-like network rich in collagen III, proteoglycans, and glycoproteins. The chorion layer is composed of a reticular layer containing collagens I, III, IV, V, and VI and proteoglycans; a basement membrane layer containing collagen IV, fibronectin, and laminin; and a trophoblast layer.⁶ Together, the amniotic membrane is a fibrous tissue containing many ECM components (Fig. 1). Some of the many factors present in this bioactive ECM include platelet-derived growth factors (PDGFs), transforming growth factor- β 1 (TGF- β 1), basic fibroblast growth factor, and granulocyte colony-stimulating factor, as well as interleukin-4 (IL-4), IL-6, IL-8, and IL-10.⁷ The crucial roles of this metabolically active tissue are to function as a barrier for water and soluble material transport, to synthesize growth factors and cytokines, and to regulate amniotic fluid pH.¹

Amniotic Membrane Allografts

Native ECM materials such as amniotic membrane represent a class of naturally derived biomaterials already used in the clinic for tissue healing applications.^{8,9} Amniotic membrane was used as early as 1910 for skin grafting¹⁰ and has been used successfully for healing of various tissues including skin,^{11,12} cornea,^{13,14} and ligament¹⁵ in clinical settings, as well as cartilage and cardiac repair in preclinical animal models.^{16–18} In addition to being nutrient-rich tissues with the ability to stimulate soft tissue development, amniotic membrane acts as a nonimmunogenic barrier between the mother and fetus during pregnancy; therefore, amniotic allograft tissue can be transplanted without rejection by the host, as observed in clinical applications.^{11,15,19}

Typically, amniotic membrane is harvested upon scheduled cesarean section from donors who undergo rigorous screening for viral and infectious diseases, including human immunodeficiency virus 1 and 2, hepatitis B and C, human T-cell lymphotropic virus, and syphilis.^{20,21} After washing and cleaning harvested tissues in buffered solutions, amniotic membrane grafts can be prepared as fresh or preserved allografts. When using fresh amniotic membrane grafts, immediate transplantation is often necessary²²; therefore, preservation techniques such as cryopreservation or dehydration have been utilized to increase storage time. Although both preservation methods have exhibited diminished maximum loads to failure and elongation to failure in tension compared with fresh tissue, the structural components and integrity of the tissue remain intact with both techniques.²³ One drawback to cryopreservation is that the graft

From the *MiMedx Group Inc., Marietta, GA; and †Department of Agriculture and Biological Engineering, Mississippi State University, Starkville, MS.

Supported by MiMedx Group Inc.

The authors disclose that they are employees of MiMedx Group Inc.

For reprint requests, or additional information and guidance on the techniques described in the article, please contact Jennifer Lei, PhD, at jlei@mimedx.com or by mail at MiMedx Group Inc., 1775 West Oak Commons Court NE, Marietta, GA 30062. You may inquire whether the author(s) will agree to phone conferences and/or visits regarding these techniques.

Supplemental Digital Content is available for this article. Direct URL citations appear in the printed text and are provided in the HTML and PDF versions of this article on the journal's Website, www.techortho.com. Copyright © 2017 The Author(s). Published by Wolters Kluwer Health, Inc. This is an open-access article distributed under the terms of the Creative Commons Attribution-Non Commercial-No Derivatives License 4.0 (CCBY-NC-ND), where it is permissible to download and share the work provided it is properly cited. The work cannot be changed in any way or used commercially without permission from the journal.

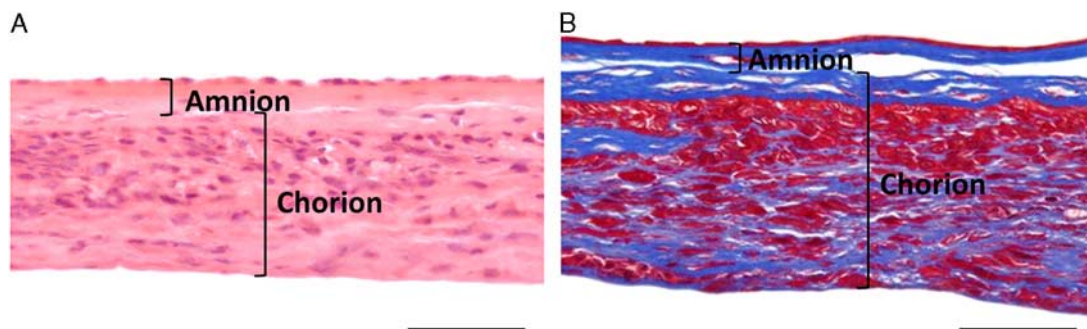


FIGURE 1. Histologic images of dehydrated amniotic membrane allografts. Amnion and chorion layers are delineated. A, Hematoxylin and eosin staining of amniotic membrane. Hematoxylin (purple) stains cell nuclei and eosin (pink) stains proteins. B, Masson trichrome staining of dehydrated human amnion/chorion membrane. Red staining represents keratin and fibrous protein, blue staining represents collagen. Scale bar = 50 μ m.

must be maintained in its frozen state, thus requiring storage and transportation at low temperatures, usually in the range of -80°C or below, and in the presence of potentially cytotoxic cryoprotectants.

An alternative method of dehydration removes moisture, which reduces enzymatic activity and inhibits viability of microorganisms. One patented procedure (PURION) for processing human amnion/chorion involves gentle cleansing, lamination of the amnion and chorion, and dehydration of the tissues under controlled conditions,²⁴ resulting in a dehydrated human amnion/chorion membrane (dHACM) as defined by in the United States Pharmacopeia and the National Formulary (USP-NF) monograph “Tissue Human Amnion Chorion Membrane Dehydrated.”²⁵ dHACM allografts can be used in both membrane form and micronized form, in which the latter is membrane tissue that has been cryomilled and sieved using 180 and 25 μ m sieves for particulate sizing.²⁴ The micronized tissue is typically reconstituted in a saline solution and administered to patients as a flowable allograft. Previous studies have identified over 226 growth factors, cytokines, chemokines, and protease inhibitors, many of which function to stimulate paracrine responses in fibroblasts, endothelial cells, and stem cells to promote tissue healing and repair.^{7,26,27} In addition, these bioactive factors, including epidermal growth factor (EGF), fibroblast growth factor-4 (FGF-4), and TGF- β 1 are known to promote proliferation, migration, and secretion of paracrine factors by fibroblasts, endothelial cells, and a variety of adult stem cells, including bone marrow-derived mesenchymal stem cells, adipose-derived stem cells and hematopoietic stem cells.^{28–30} In a mouse subcutaneous implant model, increased hematopoietic stem cell recruitment and enhanced angiogenesis was demonstrated in response to dHACM implants.²⁹ These studies demonstrate that dHACM contains active growth factors and other biomolecules that retain the ability to direct or supplement biological activity, for example, by regulating endogenous cells in a wound environment.

When comparing similar commercially available placental-derived flowable products, growth factor content in micronized dHACM (MiMedx Group Inc., Marietta, GA), “chorion-free cryopreserved amnion and amniotic fluid” (FloGraft FREEDOM; Applied Biologics), and “placental tissue matrix” (PX50; Skye Biologics) was measured using a multiplex enzyme-linked immunosorbent assay array by an independent contract research organization. Detailed methods containing how this analysis was performed is available in the Supplemental Information, Supplemental Digital Content 1, <http://links.lww.com/TIO/A5>. The results presented are shown as the measured concentration

of a factor in either product normalized to the measured concentration in micronized dHACM (denoted by the horizontal blue line at 100%). It was observed that 48 of the 64 factors that were detected in micronized dHACM were not detected in the “amnion and amniotic fluid” product, and of the factors detected in both products, 14 of 16 factors were measured at significantly greater levels in micronized dHACM (Fig. 2; $P < 0.05$). When comparing micronized dHACM to the “placental tissue matrix” product, 54 of the 64 factors detected in micronized dHACM were not detected in the placental tissue matrix, and of those detected in both, 8 of 10 factors were found to be significantly greater in micronized dHACM (Fig. 3; $P < 0.05$). Overall, 62 of 64 factors (96.8%) were measured at levels significantly higher in micronized dHACM compared with both the “amnion and amniotic fluid” and the “placental tissue matrix” products (Figs. 2, 3). In total, these products contained only 1% to 2% of the total content of growth factors, cytokines, and chemokines that dHACM contained, suggesting that dHACM retains high levels of growth factors, cytokines, and chemokines that can be delivered to promote soft tissue healing. Owing to their rich biological content—a cocktail of growth factors and cytokines, including immunomodulatory molecules—as well as the structural integrity afforded by the abundance of collagens and proteoglycans, amniotic membrane may be beneficial in many orthopedic soft tissue healing applications.

dHACM Clinical Applications

Overall, hundreds of thousands of PURION Processed dHACM grafts have been utilized clinically to promote healing in a variety of applications including skin and corneal wounds, periodontal surgery, and soft tissue repair, with no known adverse events as a result of the use of these tissues.^{11,31} Recently, amniotic membrane sheets processed by this method demonstrated greatly improved healing of diabetic foot ulcers¹² and venous leg ulcers¹¹ compared with the clinical standard compression therapy in randomized controlled clinical trials.

Diabetic foot and venous leg ulcers, lower extremity complications that commonly occur in people with poor circulation and neuropathy, are slow healing chronic wounds that can result in severe morbidity.³¹ In a randomized controlled trial of amniotic membrane grafts, patients with diabetic foot ulcers were either given standard of care treatment with a collagen-alginate dressing or standard of care treatment with dHACM application every 2 weeks. After 4 weeks, wound size was reduced $97.1\% \pm 7\%$ in patients receiving dHACM treatment, compared with the $32.0\% \pm 47.3\%$ closure in patients receiving standard of care treatment.¹⁹ By week six, 12 of 13 patients

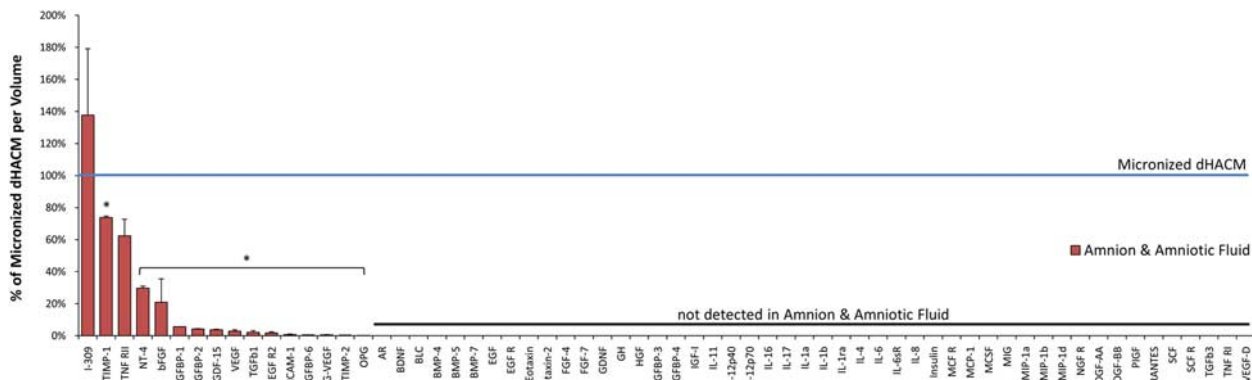


FIGURE 2. Growth factor, cytokine, and chemokine content in cryopreserved flowable amnion and amniotic fluid normalized to growth factor, cytokine, and chemokine content measured in micronized dehydrated human amnion/chorion membrane (dHACM), as performed by an independent contract research organization. Content in dHACM is depicted by the horizontal blue line at 100%. Content in the amnion and amniotic fluid is depicted relative to dHACM by the red bars. Sixty-two of 64 measured factors were significantly higher in dHACM than the amnion and amniotic fluid. *Significant difference for that molecule compared with micronized dHACM; n=5; P≤0.05. Values reported represent mean ± SD.

receiving dHACM treatment reported healed ulcers compared with only 1 of 12 patients receiving standard of care treatment.¹⁹ In addition, wounds did not recur with long-term follow-up after up to 12 months demonstrating robust healing and repair.³² In a study comparing dHACM application to standard compression therapy for venous leg ulcers, 62% of the patients receiving the allograft exhibited more than 40% wound closure after 4 weeks, which was significantly greater than 32% of patients receiving compression therapy.¹¹ Forty percent closure was validated as a predictive end point with 80% of venous leg ulcers undergoing 40% closure within 4 weeks progressing to complete closure within 24 weeks, compared with an only 33% healing rate of wounds with <40% closure.³³ Overall, it has been observed that for both diabetic foot ulcers and venous leg ulcers, application of membrane dHACM is an effective therapy to heal chronic wounds rapidly and has significant improvements compared with standard therapies.^{12,33,34} Although dHACM allografts have typically been used to heal chronic dermal wounds, their regenerative properties with the ability to reduce scar tissue formation, modulate inflammation, and enhance healing make them a potentially effective treatment option for healing of other tissues.

ORTHOPEDIC TISSUE HEALING

Orthopedic soft tissue healing occurs in similar process to wound healing. The 3 main phases are the inflammatory phase, the proliferation phase, and the remodeling phase. The initial inflammatory phase occurs immediately after the injury and can last up to 1 to 3 days, during which increased blood flow helps increase fibrin clot formation and form a mesh to trap any foreign particles and debris. Mast cells and neutrophils are recruited to the site to help phagocytose damaged tissue or debris and release cytokines, such as tumor necrosis factor-α, IL-1α, IL-1β, TGF-β1, granulocyte colony-stimulating factor, and macrophage colony-stimulating factor.³⁵ These cytokines help recruit other inflammatory cells, such as monocytes/macrophages and lymphocytes, that stimulate the proliferative phase of the healing process.³⁶ The proliferative phase begins 24 to 48 hours after injury and persists for 2 to 3 weeks. During the proliferation phase, resident tissue cells migrate to the area from surrounding tissues and are activated by factors released by local macrophages. Upon activation, these cells, which include fibroblasts for fibrous tissues or local stem cells,

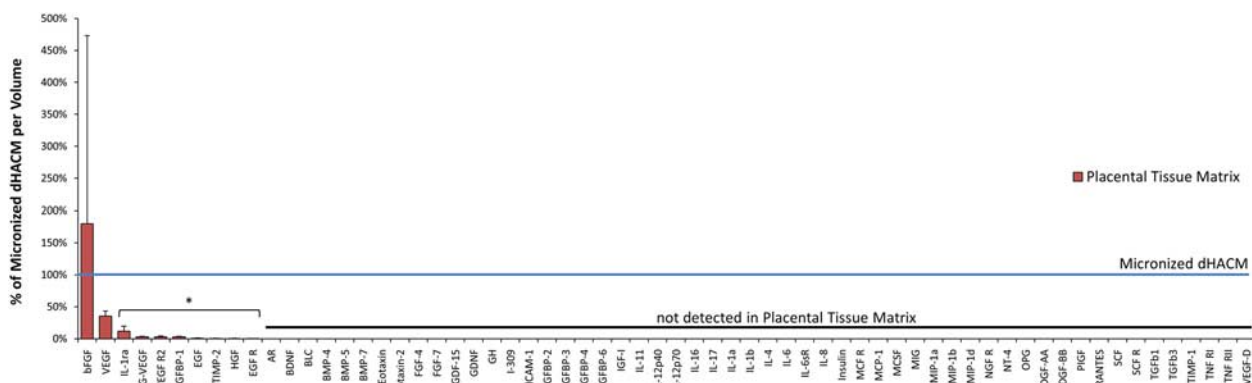


FIGURE 3. Growth factor, cytokine, and chemokine content in flowable placental tissue matrix normalized to growth factor, cytokine, and chemokine content measured in micronized dehydrated human amnion/chorion membrane (dHACM), as performed by an independent contract research organization. Content in dHACM is depicted by the horizontal blue line at 100%. Content in the placental tissue matrix is depicted relative to dHACM by the red bars. Sixty-two of 64 measured factors were significantly higher in dHACM than the placental tissue matrix. *Significant difference for that molecule compared with micronized dHACM; n=5; P≤0.05. Values reported represent mean ± SD.

proliferate and secrete disorganized collagen-based tissue. In addition, secretion of factors such as macrophage-derived factors, PDGF, and FGF result in the formation of developing capillaries and angiogenesis of the scar tissue.³⁷ Resolution of tissue healing ends with the remodeling phase that results in the formation of organized collagen fibers that resembles the original tissue as closely as possible. The initial deposition of collagen fibers during the proliferative phase are relatively weak fibrils; therefore, during remodeling, the fibers organize and align themselves in the direction of local stresses to create a fibrous tissue that may not exactly recapitulate the original tissue structure, but does restore full functional utility.^{35,37}

Although tissue healing is a complex process, therapies that can intervene or support such events can be beneficial to the repair process to produce the best quality tissue in minimal time. Appropriate interventions, such as modulating the inflammatory response to maximize recruitment of cells or refining the scar tissue formation during the proliferative and remodeling phases, can be used to effectively produce a healed tissue that best resembles the structure and function of the original tissue before injury.³⁸

AMNIOTIC MEMBRANE APPLICATIONS FOR ORTHOPEDIC TISSUES

Typically, for orthopedic tissue injuries, current repair techniques often only address restoring mechanical function by reattachment or replacement of the tissue. For example, tendon and ligament repair in knee joints use autografts or allografts to physically reconnect the tissues.³⁹ Although the patient may exhibit decreased pain and return to functional usage at the site of injury, the biological structure of that tissue is not reproduced, which can increase the potential for future reinjury. By using alternative methods to both restore function and regenerate tissue with structure similar to that of its native form, both repair and regeneration of injured orthopedic tissues can potentially be achieved.

Alternative methods of repairing orthopedic tissues involve the application of bioactive factors, such as tissue engineering strategies using growth factors, scaffolds and stem cells, that can promote healing and regeneration of the tissue itself.^{40,41} The amniotic membrane is a natural ECM biomaterial that contains many growth factors, cytokines, proteases, and regulatory inhibitors that can contribute to the process of soft tissue healing.^{20,28} dHACM allografts have shown clinical success in healing poorly vascularized chronic wounds and therefore have promising potential to also promote healing in less vascularized orthopedic tissues like tendon, ligament, and cartilage. Owing to these characteristics, amniotic membrane allografts have recently been used in soft orthopedic tissues and spine applications to reduce pain, prevent scar tissue formation, and promote healing. An overview of clinical usages of dHACM for repair of orthopedic tissues is summarized in Table 1.

Tendon and Ligament Repair

The incorporation of amniotic membranes tissues can decrease fibrous collagen deposition scar formation *in vitro* and modify inflammatory responses of tenocytes.⁵² Compared with adult wound healing, fetal wound healing has the ability to form highly aligned and organized fibers with minimal scar formation,⁵³ suggesting that fetal tissues and the fetal environment may be uniquely capable of supporting tissue regeneration. Therefore, one approach to recapitulate fetal healing is to use ECM-based biomaterials that originate from environments with anti-inflammatory and antimicrobial properties, such as amniotic

tissue. It was shown that when amniotic membrane tissue was incorporated into tenocyte-laden collagen-glycosaminoglycan scaffolds, cells exhibited increased metabolic activity in both basal and proinflammatory environments (induction with IL-1 β) compared with scaffolds without amniotic tissue.⁵² In addition, the addition of amniotic membranes also downregulated the gene expression of the proinflammatory molecules tumor necrosis factor- α and matrix metalloproteinase-3 in tenocytes, indicating that this biomaterial could alter the inflammatory response associated with scar formation in tendon healing to better mimic fetal soft tissue healing.⁵² Methods of incorporating hyaluronic acid (HA) have also been explored to reduce scar formation, as HA is known to play a role in chronic wound healing by promoting cell proliferation and motility.^{54,55} As a critical component of several orthopedic tissues including cartilage and synovial fluid, HA contributes both mechanical properties as well as the ability to regulate cellular activity through interaction with growth factors and binding of cell surface receptors, such as CD44. In particular, HA is an ECM component that has been detected and quantified in dHACM tissues and may play a role in improved soft tissue healing.⁵⁶ Thus, the use of amniotic membranes that contain HA could potentially be an effective method to help modulate the inflammatory environment to decrease scar formation during tendon and ligament healing.

In flexor tendon transection models in chickens, it has been shown that the use of amniotic membranes can improve flexor tendon repair.^{57,58} Zone II flexor tendon injuries can lead to loss of hand functions due to the formation of fibrous adhesions and restriction of tendon gliding. One approach to prevent tissue adhesion formation is to use membranous materials, such as amniotic membrane allografts, which can act as a barrier between the healing tendon and the surrounding tissue environment. In white leghorn chickens, digital flexor tendons were incised and repaired with a modified Kessler stitch, and amniotic membrane was sutured to the tendon proximally and distally away from the cut ends, ultimately surrounding the repaired tendon tissue.⁵⁷ By week 12, histologic analysis revealed that tendons covered with the amniotic membrane did not exhibit granulation tissue or fibrous adhesions, as was observed with groups without amniotic membrane intervention.⁵⁷ In addition, organized, aligned collagen fibers were observed throughout the healed tendon.⁵⁷ Using the Tang scale to evaluate adhesion formation, it was determined that amniotic membrane coverage was beneficial in preventing adhesion when compared with repaired tendons without the graft. Collectively, these data demonstrate that the amniotic membrane can be used to assist in the treatment of reconstructed tendons and prevention of adhesions.

Clinical applications of dHACM for tendon and ligament tissue repair have recently been used in the treatment of plantar fasciitis, anterior cruciate ligament (ACL) reconstruction, rotator cuff injury, tennis elbow, and Achilles tendinopathy (Table 1). For treatment of plantar fasciitis, a prospective, randomized, blinded clinical trial with 45 patients revealed that micronized dHACM administration is a viable treatment option to decrease pain. Micronized dHACM was first reconstituted in 0.9% saline at 0.5 or 1.25 cc. For administration of either the dHACM treatment or saline control, patients received a 2 cc injection of Marcaine to the medial origin of the plantar fascia, followed by an injection of 0.9% saline control or 0.9% saline containing the reconstituted micronized dHACM. The needle was placed down to the periosteum of the heel and the treatment was delivered. Using the American Orthopaedic Foot and Ankle Society Hindfoot Scale, it was observed that patients receiving either 0.5 or 1.25 cc of dHACM injection significantly increased their score when

TABLE 1. Case Study Examples of dHACM Clinical Applications for Treatment of Orthopedic Injuries

Application	Injury	dHACM Administration	Amount Administered	Patient Size	Results	References
Tendon	Supraspinatus tendon tear	dHACM injection supplemented after tendon reattachment	NA	1	Rotator cuff strength returned to normal after 7 wk	42
	Common extensor tendon tear	dHACM injection 8 and 11 mo after injury diagnosis	40 mg	1	80% reduction of symptoms after 1 treatment; complete resolution after second treatment	43
	Lateral epicondylitis	Single dHACM injection immediately after injury diagnosis	0.5 cc	5	4/5 patients reported reduced symptoms after 3 mo	44
	Patellar tendon partial tear	Single dHACM injection 6 mo after injury diagnosis	40 mg	1	Patient reported >90% improvement of symptoms after 5 wk	45
	Supra/infraspinatus tendinitis and partial tears	Single dHACM injection 8 mo after injury diagnosis	40 mg	1	Ultrasound revealed soft tissue healing and patient reported reduced symptoms by >90% after 4 mo	46
Ligament	Achilles tendinopathy	Single dHACM injection 1 mo after injury diagnosis	100 mg	22	72.7% patients experienced decreased pain with corresponding increases in activity and function	47
	ACL reconstruction	Hamstring autograft augmented with dHACM allograft patch	Patch	1	MRI revealed vascularization of autograft and continued healing 6 mo postoperation; patient returned to normal gait after 10 wk and returned to full sports activity after 8 mo	48
	Chronic and refractory plantar fasciitis	Single dHACM injection after 10 mo of persistent pain	40 mg	10	Ultrasound revealed 19% decrease in thickness of fascia; 10/10 patients reported significantly reduced pain after 4 mo	49
	Plantar fasciitis	Single dHACM injection after 12 mo of traditional treatments	0.5 or 1.25 cc	44	At weeks 1-8, patients reported significantly lower AOFAS hindfoot pain scores compared with control patients	15
	Plantar fasciitis	Single dHACM injection	40 mg	20	16/20 patients reported complete pain reduction after 3 mo; 17/20 patients reported improvement in activity and function after 3 mo	50
Spine	TLIF	dHACM membrane placed in epidural space after insertion of fusion device	Patch	5	After 12 mo, dHACM barrier appeared to reduce epidural fibrosis; patients reported significantly decreased Oswestry Disability Index scores compared with scores before surgery, indicating lower back pain levels	51

Data gathered from clinical trial reports, poster presentations or internal clinical reports. Patient data were collected and performed under informed consent and approval of an institutional review board was obtained.

ACL indicates anterior cruciate ligament; AOFAS, American Orthopaedic Foot and Ankle Society; dHACM, dehydrated human amnion/chorion membrane; NA, data not available; ODI, Oswestry Disability Index; TLIF, transforaminal lumbar interbody fusion.

compared with baseline scores and had significantly greater scores when compared with patients receiving the control saline treatments.¹⁵ This increase in score represented decreased pain and greater function in the foot. Owing to the many growth factors contained in the dHACM tissue, biomolecules such as EGF, TGF- β , FGF, and PDGF-AA and PDGF-BB may stimulate cell migration and proliferation, as well as metabolic processes such as collagen synthesis to help initiate tendon healing.⁵⁹ In another case study, a dHACM allograft patch was used to supplement a ruptured ACL that was reconstructed using a hamstring autograft.⁴⁸ During the arthroscopic ACL reconstruction procedure, the hamstring autograft was augmented with a dHACM allograft patch fixated using the Tape Locking Screw (TLS) technique. The autografts were wrapped in dHACM and rolled around 2 posts to form a 4-strand closed loop with TLS strips passed through 2 ends of the tendon loops. Subsequent magnetic resonance

imaging scans revealed vascularization in the hamstring graft tissue as early as 3 months post-operative and the patient's rehabilitation progressed successfully with regards to strength and proprioception at 8 months post-operative. Although the sample size was small for this study, this represents another example of dHACM uses in clinical practices for treatment of tendon and ligament injuries.

Taken together, recent preclinical and clinical findings suggest that the administration of dHACM allografts is a viable option to treat tendon and ligament injuries. The ability to modulate the cellular inflammatory environment may decrease pain and promote scarless healing without the formation of fibrous tissue, thus supporting the regeneration of injured tendon tissues.^{52,57} In addition, dHACM may be beneficial as an adjuvant, based on the success of clinical cases of tendon and ligament healing when dHACM allografts have supplemented repair treatments.^{15,48}

Cartilage and Joint Space Repair

Amniotic membrane has demonstrated potential for cartilage healing/regeneration in in vitro and in vivo models. Human articular chondrocytes cultured on the basement membrane of cryopreserved human amnion maintained viability and migrated into cartilage tissue explants.⁶⁰ In addition, hybrid, 3-dimensional, cell-seeded scaffolds composed of homogenized, lyophilized amniotic membrane, and fibrin supported both maintenance of chondrocyte phenotype and glycosaminoglycan production.⁶¹ Lastly, scaffolds containing rabbit chondrocytes seeded on the stromal layer of human amnion led to collagen type II production in vitro, and repair of osteochondral defects after 8 weeks in a rabbit model.¹⁶ These studies represent examples of amniotic membrane usages in tissue engineering applications to help support cell-based healing of cartilage tissue both in vitro and in vivo.

Synoviocytes found within the lining of the joint capsule (synovial membrane) are known to maintain homeostasis of the joint space by producing specialized matrix components, such as HA, collagens, and fibronectin into the synovial fluid.⁶² In degenerative joint diseases, such as osteoarthritis (OA) and rheumatoid arthritis (RA), cartilage undergoes loss of proteoglycans and disruption of collagen fibers, whereas synoviocytes often exhibit hyperplasia.^{63,64} Treatments of intra-articular HA injection have been shown to be effective in reducing pain in patients with OA, potentially due to HA's ability to reduce nerve impulses and nerve sensitivity associated with pain.⁶⁵⁻⁶⁷ Furthermore, it has been shown that HA has chondroprotective effects, in which HA binding to CD44 can stimulate chondrocyte production of tissue inhibitors of matrix

metalloproteinases (TIMPs) that inhibit cartilage degradation and promote cell proliferation and ECM production.⁶⁸ When examining effects of extracts of micronized dHACM on synoviocytes harvested from synovium of donors without arthritic disease, donors with OA and donors with RA (cell applications) it was observed that micronized dHACM extracts promoted significant upregulation of HA synthase (HAs) 1 and 2 gene expression over the course of 3 days in all 3 cell types when compared with nontreated cells (basal and complete) (Fig. 4). Methods for the experimental setup of these experiments can be seen in the Supplemental Information, Supplemental Digital Content 1, <http://links.lww.com/TIO/A5>. In addition, it was observed that HA production significantly increased in synoviocytes from RA synovium when treated with the lower dosage (1 mg/cc) of dHACM extracts (Fig. 4). Although the exact mechanism of HA production by the synoviocytes is not clear, it is known that endogenous synthesis of HA can be stimulated by supplementation with an external source of HA and TGF-β1, EGF and IL-1β.^{69,70} Therefore, the upregulation in HA synthase expression could be caused by the stimulation of the HA, growth factors, and cytokines contained within the allograft tissue. The administration of dHACM for treatment of joint diseases could be potentially effective in reducing pain and regenerating tissue due to the delivery of HA and other ECM components, as well as the cocktail of bioactive growth factors and inhibitors found in the tissue allograft.

In a medial meniscal transection-induced model of OA in Lewis rats, micronized dHACM injected intra-articularly slowed the progression of the disease.¹⁷ Histologic staining at day 3 and at day 21 revealed that the micronized dHACM

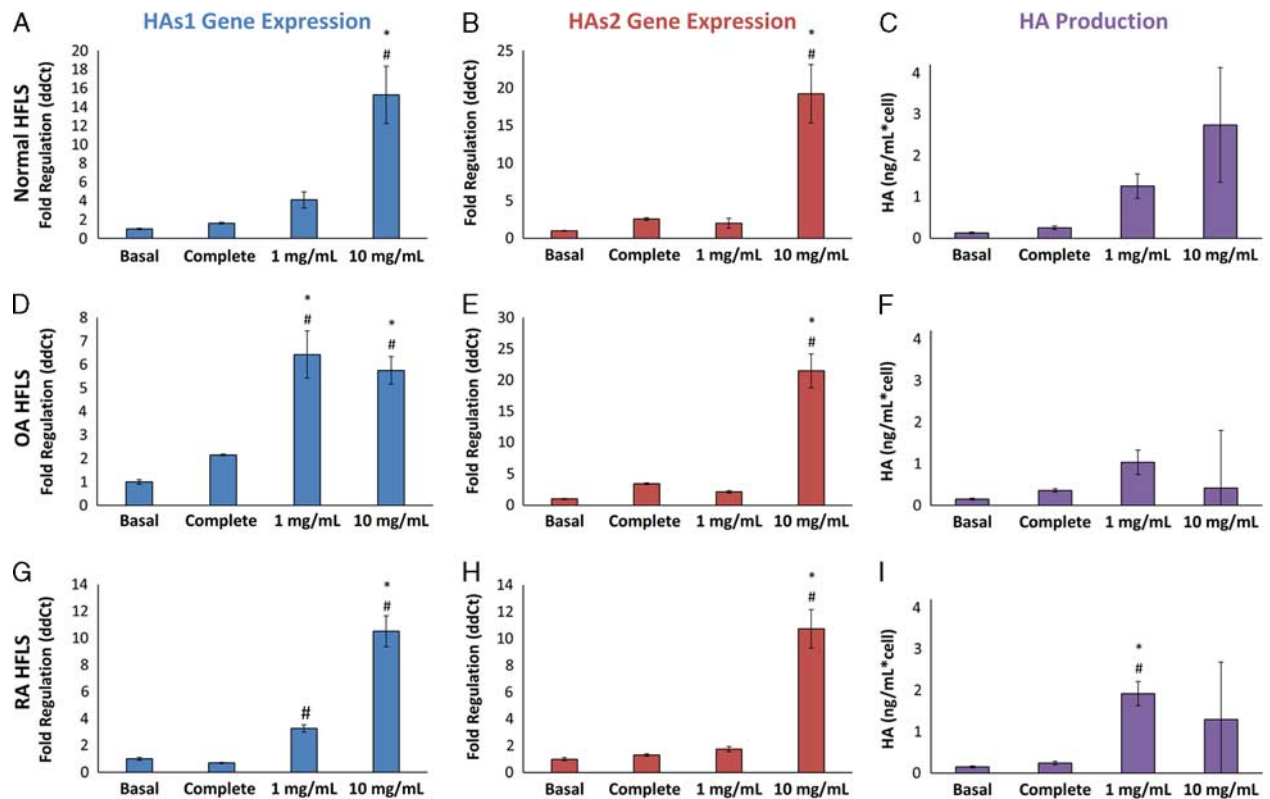


FIGURE 4. Hyaluronic acid synthase 1 (HAS1), HAS2 gene expression, and hyaluronic acid (HA) production by micronized-treated human fibroblast-like synoviocytes (HFLS) from normal synovium, osteoarthritis synovium (OA), and rheumatoid arthritis synovium (RA). Normal HFLS (A–C), OA HFLS (D–F); RA HFLS (G–I). *Significant difference compared with basal group; #Significant difference compared with complete group; n=5; P<0.05. Values reported represent mean ± SD.

allograft incorporated into the surrounding synovial tissue soon after administration and remained localized to the joint for up to 21 days.¹⁷ Using equilibrium partitioning of an ionic contrast agent micro-computed tomography imaging, no cartilage lesions were measured, and both the number of partial erosions and proteoglycan loss were significantly reduced at 21 days in animals receiving micronized dHACM treatment compared with saline-treated control medial meniscal transection animals.¹⁷ Possible mechanisms by which dHACM administration can attenuate cartilage degradation and OA progression is through the delivery of a cocktail of growth factors (PDGF, TGF- β , basic fibroblast growth factor, EGF, placental growth factor), anti-inflammatory molecules (IL-4, IL-10), TIMP-1, TIMP-2, and TIMP-4, as well as ECM components contained in dHACM tissue. These biomolecules can potentially maintain cartilage homeostasis, reduce inflammation, and reduce matrix metalloproteinase expression that is active in diseased joints.

Collectively, *in vitro* data suggest that amniotic membrane may serve as an effective scaffold for cell delivery in cartilage tissue engineering applications and can act as a supportive ECM platform to promote cartilage repair. Preclinical data also revealed that dHACM allografts can be administered as a disease modifying therapy for OA. In both cases, the utilization of amniotic membrane, specifically dHACM allografts, can be beneficial in therapies for cartilage injury and disease.^{16,17}

Spinal Repair

Similarly to its function *in situ*, amniotic membrane, in particular dHACM, has been used successfully during surgical procedures as a barrier membrane to minimize post-laminectomy epidural adhesions and scarring. These outcomes have been associated with reduction in pain following these spinal procedures. In a rat model, amniotic membrane placed around the laminectomy site led to less epidural fibrosis adjacent to the dura and minimal scar tissue adherence to the dura.⁷¹ Similarly, cross-linked amniotic membrane covering the dura matter reduced fibroblast infiltration and scar tissue formation compared with animals receiving no treatment in a dog model of laminectomy.⁷²

In a clinical case study, 5 patients underwent transforaminal lumbar interbody fusion with implantation of dHACM in the epidural space to observe effects on scarring and patient reported pain. After insertion of the interbody fusion device, bone graft material and posterior stabilization devices, the dHACM allograft was cut to fit the dura exposed by the decompression, and placed in the epidural space. Overall, minimal scarring in the epidural space and significantly lower patient pain scores postsurgery were reported. Of note, dHACM facilitated easy separation of the tissues in revision surgery for 4 of the 5 patients.⁵¹ Although in this study patient size was too small to evaluate the effectiveness of dHACM as a barrier membrane to prevent epidural fibrosis, it showed promising results in achieving that goal in future utilizations of the allograft in vertebral spine fusion applications.

CONCLUSIONS

Amniotic membrane-based allografts are classified as a naturally derived biomaterial and are currently being used in wound and soft tissue repair applications. Characterization of this tissue has revealed many growth factors, cytokines, and protease inhibitors contained within dHACM tissue that can play a role in wound repair. dHACM has been shown to stimulate cellular activity including proliferation, migration, and secretion of soluble paracrine factors *in vitro*, and has also

demonstrated the ability to recruit reparative adult stem cells to the site of dHACM implantation *in vivo*. In addition, these allografts have been shown in randomized clinical trials to be effective in healing various dermal and soft tissue wounds. Because of their regenerative properties, dHACM may also be used to repair and regenerate orthopedic tissues. To date, amniotic membrane and dHACM have been evaluated for repair of tendon and ligament, attenuation of cartilage and joint space diseases, and prevention of scarring and adhesion formation in spinal fusion procedures. dHACM allografts can be used both as a therapy to decrease pain and reduce fibrous tissue formation, for example in plantar fasciitis treatment, or as a supplement patch to a current procedure being performed, for example in spinal transforaminal lumbar interbody fusion or ACL reconstruction. Clinical usage in orthopedic repair is rapidly growing and many ongoing clinical trials using dHACM allografts in plantar fasciitis treatments, Achilles tendon repair, lumbar decompression and microdiscectomy and total knee arthroplasty are underway (<http://clinicaltrials.gov>).⁵ Current research and clinical cases using amniotic membrane for repairing orthopedic tissues have shown that dHACM allografts can have promising results in repairing injured and diseased tissues due to their ability to deliver a natural ECM biomaterial that contains many active biomolecules. There is great potential for the use of amniotic membrane allografts for regenerative applications in orthopedics; however, much more research will be necessary to specifically define what those applications will be.

REFERENCES

- Mamede AC, Carvalho MJ, Abrantes AM, et al. Amniotic membrane: from structure and functions to clinical applications. *Cell Tissue Res*. 2012;349:447–458.
- Toda A, Okabe M, Yoshida T, et al. The potential of amniotic membrane/amnion-derived cells for regeneration of various tissues. *J Pharmacol Sci*. 2007;105:215–228.
- Fukuda K, Chikama T, Nakamura M, et al. Differential distribution of subchains of the basement membrane components type IV collagen and laminin among the amniotic membrane, cornea, and conjunctiva. *Cornea*. 1999;18:73–79.
- Malak TM, Ockleford CD, Bell SC, et al. Confocal immunofluorescence localization of collagen types I, III, IV, V and VI and their ultrastructural organization in term human fetal membranes. *Placenta*. 1993;14:385–406.
- Riboh JC, Saltzman BM, Yanke AB, et al. Human amniotic membrane-derived products in sports medicine: basic science, early results, and potential clinical applications. *Am J Sports Med*. 2016;44:2425–2434.
- Niknejad H, Peirovi H, Jorjani M, et al. Properties of the amniotic membrane for potential use in tissue engineering. *Eur Cells Mater*. 2008;15:88–99.
- Koob TJ, Rennert R, Zabek N, et al. Biological properties of dehydrated human amnion/chorion composite graft: implications for chronic wound healing. *Int Wound J*. 2013;10:493–500.
- Ilic D, Vicovac L, Nikolic M, et al. Human amniotic membrane grafts in therapy of chronic non-healing wounds. *Br Med Bull*. 2016; 117:59–67.
- Fetterolf DE, Snyder RJ. Scientific and clinical support for the use of dehydrated amniotic membrane in wound management. *Wounds*. 2012; 24:299–307.
- Davis JW. Skin transplantation with a review of 550 cases at the Johns Hopkins Hospital. *Johns Hopkins Med J*. 1910;15:307.
- Serena TE, Carter MJ, Le LT, et al. EpiFix VLUSG. A multicenter, randomized, controlled clinical trial evaluating the use of dehydrated

- human amnion/chorion membrane allografts and multilayer compression therapy vs. multilayer compression therapy alone in the treatment of venous leg ulcers. *Wound Repair Regen.* 2014;22:688–693.
12. Zelen CM, Serena TE, Denozieri G, et al. A prospective randomised comparative parallel study of amniotic membrane wound graft in the management of diabetic foot ulcers. *Int Wound J.* 2013;10:502–507.
 13. De Roth A. Plastic repair of conjunctival defects with fetal membrane. *Arch Ophthalmol.* 1940;23:522–525.
 14. Lee SH, Tseng SC. Amniotic membrane transplantation for persistent epithelial defects with ulceration. *Am J Ophthalmol.* 1997;123:303–312.
 15. Zelen CM, Poka A, Andrews J. Prospective, randomized, blinded, comparative study of injectable micronized dehydrated amniotic/chorionic membrane allograft for plantar fasciitis—a feasibility study. *Foot Ankle Int.* 2013;34:1332–1339.
 16. Jin CZ, Park SR, Choi BH, et al. Human amniotic membrane as a delivery matrix for articular cartilage repair. *Tissue Eng.* 2007;13:693–702.
 17. Willett NJ, Thote T, Lin AS, et al. Intra-articular injection of micronized dehydrated human amnion/chorion membrane attenuates osteoarthritis development. *Arthritis Res Ther.* 2014;16:R47.
 18. Lim JJ, Fonger J, Koob TJ. Dehydrated human amnion/chorion membrane allograft promotes cardiac repair following myocardial infarction. *J Cardiol Cardiovasc Ther.* 2017;2:555599.
 19. Zelen CM, Gould L, Serena TE, et al. A prospective, randomised, controlled, multi-centre comparative effectiveness study of healing using dehydrated human amnion/chorion membrane allograft, bioengineered skin substitute or standard of care for treatment of chronic lower extremity diabetic ulcers. *Int Wound J.* 2015;12:724–732.
 20. Koob TJ, Lim JJ, Masee M, et al. Properties of dehydrated human amnion/chorion composite grafts: implications for wound repair and soft tissue regeneration. *J Biomed Mater Res B Appl Biomater.* 2014;102:1353–1362.
 21. Koob TJ, Lim JJ, Zabek N, et al. Cytokines in single layer amnion allografts compared to multilayer amnion/chorion allografts for wound healing. *J Biomed Mater Res B Appl Biomater.* 2015;103:1133–1140.
 22. Ricci E, Vanosi G, Lindenmair A, et al. Anti-fibrotic effects of fresh and cryopreserved human amniotic membrane in a rat liver fibrosis model. *Cell Tissue Bank.* 2013;14:475–488.
 23. Niknejad H, Deihim T, Solati-Hashjin M, et al. The effects of preservation procedures on amniotic membrane's ability to serve as a substrate for cultivation of endothelial cells. *Cryobiology.* 2011;63:145–151.
 24. Daniel J, Tofe R, Spencer R, et al. *Placental Tissue Grafts.* USA: MiMedx Group Inc.; 2012.
 25. United States Pharmacopeia and National Formulary Monograph. Tissue Human Amnion Chorion Membrane Dehydrated. USP 40—NF 352017. 6486–6487.
 26. Masee M, Chinn K, Lei J, et al. Dehydrated human amnion/chorion membrane regulates stem cell activity in vitro. *J Biomed Mater Res B Appl Biomater.* 2016;104:1495–1503.
 27. Lim JJ, Koob TJ. Placental cells and tissues: the transformative rise in advanced wound care. In: Fonseca C, ed. *Topics on Wound Healing.* Rijeka, Croatia: InTech; 2016. In press.
 28. Koob TJ, Lim JJ, Masee M, et al. Angiogenic properties of dehydrated human amnion/chorion allografts: therapeutic potential for soft tissue repair and regeneration. *Vasc Cell.* 2014;6:10.
 29. Maan ZN, Rennert RC, Koob TJ, et al. Cell recruitment by amnion chorion grafts promotes neovascularization. *J Surg Res.* 2015;193:953–962.
 30. Masee M, Chinn K, Lim JJ, et al. Type I and II diabetic adipose-derived stem cells respond in vitro to dehydrated human amnion/chorion membrane allograft treatment by increasing proliferation, migration, and altering cytokine secretion. *Adv Wound Care (New Rochelle).* 2016;5:43–54.
 31. Sheikh ES, Sheikh ES, Fetterolf DE. Use of dehydrated human amniotic membrane allografts to promote healing in patients with refractory non healing wounds. *Int Wound J.* 2014;11:711–717.
 32. Zelen CM, Serena TE, Fetterolf DE. Dehydrated human amnion/chorion membrane allografts in patients with chronic diabetic foot ulcers: a long-term follow-up study. *Wound Med.* 2014;4:1–4.
 33. Serena TE, Yaakov R, DiMarco D, et al. Dehydrated human amnion/chorion membrane treatment of venous leg ulcers: correlation between 4-week and 24-week outcomes. *J Wound Care.* 2015;24:530–534.
 34. Zelen CM, Serena TE, Snyder RJ. A prospective, randomised comparative study of weekly versus biweekly application of dehydrated human amnion/chorion membrane allograft in the management of diabetic foot ulcers. *Int Wound J.* 2014;11:122–128.
 35. Jimenez PA, Jimenez SE. Tissue and cellular approaches to wound repair. *Am J Surg.* 2004;187:S56–S64.
 36. Dierich MP, Forster O, Grunicke H, et al. Inflammation and phagocytosis. *J Clin Chem Clin Biochem.* 1987;25:785–793.
 37. Hardy MA. The biology of scar formation. *Phys Ther.* 1989;69:1014–1024.
 38. Watson T. An extended model of physical therapy modes of action. 16th International WCPT Congress Amsterdam: Physiotherapy; 2011. A-210-0032-02387.
 39. Yang G, Rothrauff BB, Tuan RS. Tendon and ligament regeneration and repair: clinical relevance and developmental paradigm. *Birth Defects Res C Embryo Today.* 2013;99:203–222.
 40. Hauser RA, Dolan EE, Phillips HJ, et al. Ligament injury and healing: a review of current clinical diagnostics and therapeutics. *Open Rehabil J.* 2013;6:1–210.
 41. Moshiri A. Tendon and ligament tissue engineering, healing and regenerative medicine. *J Sports Med Dopng Stud.* 2013;3:126.
 42. Sciamberg S. *Patient Case Example: Bridgefix in Arthroscopic Rotator Cuff Repair.* Marietta, GA: Mimedx Group Inc.; 2016.
 43. Desai R. *Case Study: Common Extensor Tendon Tear.* Marietta, GA: MiMedx Group Inc.; 2016.
 44. Istwan N. *White Paper: Retrospective Evaluation of Amniofix(R) Injectable Human Amniotic Membrane Allograft for the Treatment of Lateral Epicondylitis.* Marietta, GA: MiMedx Group Inc.; 2012.
 45. Desai R. *Case Study: Partial Thickness Tear Patellar Tendon Origin.* Marietta, GA: MiMedx Group Inc.; 2016.
 46. Desai R. *Case Study: Calcific Tendinitis and Partial RTC Tear.* Marietta, GA: MiMedx Group Inc.; 2016.
 47. Abrebaya A. *Amniofix Regenerative Injection in Achilles Tendinopathy, in Desert Foot.* Phoenix, AZ; 2015.
 48. Levensgood GA. Arthroscopic-assisted anterior cruciate ligament reconstruction using hamstring autograft augmented with a dehydrated human amnion/chorion membrane allograft: a retrospective case report. *Orthop Muscular Syst.* 2016;5:2.
 49. Hansen MH, Anderson JJ. *Chronic and Refractory Plantar Fasciitis Treatment With Single-dose Dehydrated Amniotic Allograft Injection, in Desert Foot.* Phoenix, AZ; 2015.
 50. Kelly K, Green H, Krause M, et al. *AmnioFix in the Treatment of Plantar Fasciitis at Orlando VAMC, in Desert Foot.* Phoenix, AZ; 2015.
 51. Subach BR, Copay AG. The use of a dehydrated amnion/chorion membrane allograft in patients who subsequently undergo reexploration after posterior lumbar instrumentation. *Adv Orthop.* 2015;2015:501202.

52. Hortensius RA, Ebens JH, Harley BA. Immunomodulatory effects of amniotic membrane matrix incorporated into collagen scaffolds. *J Biomed Mater Res A*. 2016;104:1332–1342.
53. Eming SA, Krieg T, Davidson JM. Inflammation in wound repair: molecular and cellular mechanisms. *J Invest Dermatol*. 2007;127:514–525.
54. Price RD, Myers S, Leigh IM, et al. The role of hyaluronic acid in wound healing: assessment of clinical evidence. *Am J Clin Dermatol*. 2005;6:383–402.
55. Liu Y, Skardal A, Shu XZ, et al. Prevention of peritendinous adhesions using a hyaluronan-derived hydrogel film following partial-thickness flexor tendon injury. *J Orthop Res*. 2008;26:562–569.
56. Lei J, Priddy LB, Lim JJ, et al. Identification of ECM components and biological factors in micronized dehydrated human amnion/chorion membrane. *Adv Wound Care*. 2016;6:43–53. In press.
57. Demirkan F, Colakoglu N, Herek O, et al. The use of amniotic membrane in flexor tendon repair: an experimental model. *Arch Orthop Trauma Surg*. 2002;122:396–399.
58. Ozgenel GY. The effects of a combination of hyaluronic and amniotic membrane on the formation of peritendinous adhesions after flexor tendon surgery in chickens. *Bone Joint J*. 2004;86:301–307.
59. Parolini O, Soloman A, Evangelista M, et al. Human term placenta as a therapeutic agent: from the first clinical applications to future perspectives. In: Berven E, ed. *Human Placenta: Structure and Development*. Hauppauge, NY: Nova Science Publishers; 2010:1–48.
60. Diaz-Prado S, Rendal-Vazquez ME, Muinos-Lopez E, et al. Potential use of the human amniotic membrane as a scaffold in human articular cartilage repair. *Cell Tissue Bank*. 2010;11:183–195.
61. Hussin IH, Pinguan-Murphy B, Osman SZ. The fabrication of human amniotic membrane based hydrogel for cartilage tissue engineering applications: a preliminary study. *International Federation for Medical and Biological Engineering*. In: Osman NAA, Abas WABW, Wahab AKA, et al. (eds), 5th ed. Kuala Lumpur International Conference on Biomedical Engineering. IFMBE Proceedings, vol 35. Springer, Berlin, Heidelberg; 2011.
62. Iwanaga T, Shikichi M, Kitamura H, et al. Morphology and functional roles of synoviocytes in the joint. *Arch Histol Cytol*. 2000;63:17–31.
63. Greisen HA, Summers BA, Lust G. Ultrastructure of the articular cartilage and synovium in the early stages of degenerative joint disease in canine hip joints. *Am J Vet Res*. 1982;43:1963–1971.
64. Qu Z, Huang XN, Ahmadi P, et al. Expression of basic fibroblast growth factor in synovial tissue from rheumatoid arthritis and degenerative joint disease. *Lab Invest*. 1995;73:339–346.
65. Arrich J, Piribauer F, Mad P, et al. Intra-articular hyaluronic acid for the treatment of osteoarthritis of the knee: systematic review and meta-analysis. *CMAJ*. 2005;172:1039–1043.
66. Lo GH, LaValley M, McAlindon T, et al. Intra-articular hyaluronic acid in treatment of knee osteoarthritis. *JAMA*. 2003;290:3115–3121.
67. Moreland LW. Intra-articular hyaluronan (hyaluronic acid) and hylans for the treatment of osteoarthritis: mechanisms of action. *Arthritis Res Ther*. 2003;5:54.
68. Necas J, Bartisokova L, Brauner P, et al. Hyaluronic acid (hyaluronan): a review. *Vet Med*. 2008;8:397–411.
69. Misra S, Hascall VC, Markwald RR, et al. Interactions between hyaluronan and its receptors (CD44, RHAMM) regulate the activities of inflammation and cancer. *Front Immunol*. 2015;6:201.
70. Chow G, Tauler J, Mulshine JL. Cytokines and growth factors stimulate hyaluronan production: role of hyaluronan in epithelial to mesenchymal-like transition in non-small cell lung cancer. *J Biomed Biotechnol*. 2010;2010:485468.
71. Mahar A, Allen RT, Massie J, et al. Preclinical Study of Human Allograft Amniotic Membrane as a Barrier to Epidural Fibrosis in the Early Wound of a Postlaminectomy Rat Model. NASS 26th Annual Meeting. 2011. S2-S3.
72. Tao H, Fan H. Implantation of amniotic membrane to reduce postlaminectomy epidural adhesions. *Eur Spine J*. 2009;18:1202–1212.